



Amara H. Estrada, DVM, DACVIM (Cardiology)

Name: Hansberger, Icyhot
Signalment:
Birthdate: 05/22/2020
Weight: 7.1 kg

Date: 05/26/2021
Veterinarian:
Hospital:

History and Cardiovascular Exam

Cardiovascular Exam:

BAR, MM pink, jugular veins normal, heart rate: 144 bpm, regular rhythm, no murmur, respiratory rate: 42 eupneic, lungs clear, eupneic, femoral pulses normal. Pregnant

Diagnostic Findings

Echo Study: Adequate image quality for this study.

Left Ventricle: The left ventricular chamber size, wall thickness, and systolic function are normal.

Left Atrium: The left atrial size is normal.

Right Ventricle: The right ventricular chamber size, wall thickness, and systolic function are subjectively normal.

Right Atrium: The right atrial size is subjectively normal.

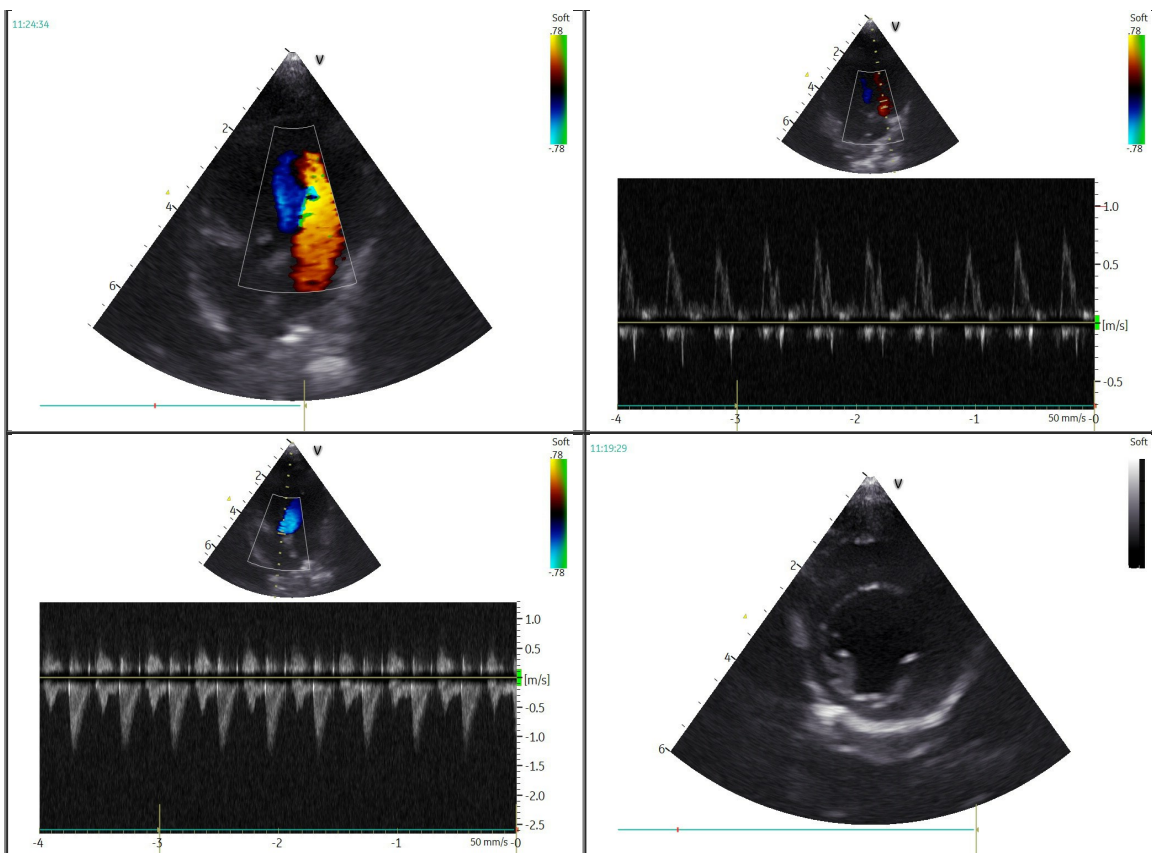
Aortic Valve: The aortic valve is trileaflet, and appears structurally normal, with normal flow across the valve in systole and no insufficiency.

Mitral Valve: The mitral valve appears normal and there is no regurgitation.

Tricuspid Valve: The tricuspid valve appears normal in structure.

Pulmonic Valve: The pulmonic valve appears structurally normal with normal Doppler flow across the valve in systole.

2D		M-Mode		Doppler	
IVSd	0.45 cm	IVSd	0.43 cm	MV E Vel	0.69 m/s
LVIDd	1.90 cm	LVIDd	1.92 cm	MV E/A Ratio	1.54
LVPWd	0.43 cm	LVPWd	0.47 cm	MV A Vel	0.45 m/s
LVIDdn	1.068	IVSs	0.61 cm	AV Vmax	1.19 m/s
IVSs	0.58 cm	LVIDs	1.14 cm	AV maxPG	5.70 mmHg
LVIDs	1.03 cm	LVPWs	0.67 cm	RVOT Vmax	0.83 m/s
LVPWs	0.61 cm	%FS	40.58 %	RVOT	
%FS	45.63 %	RWT	0.49	maxPG	2.78 mmHg
Ao Diam	0.98 cm	LVIDdn	1.077		
LA Diam	1.33 cm				
LA/Ao	1.35				



Clinical Diagnosis

Structurally and functionally normal heart

Treatment and Recommendations

Today, Icyhot's heart is structurally and functionally normal based on the echocardiogram. There are no medications indicated at this time.

Since Icyhot is of a breed that is at risk of developing heart disease, periodic rechecks are recommended. Additionally, if you notice any signs that may be consistent with heart disease such as lethargy, decreased appetite, coughing, weakness/collapse, increased respiratory effort or rate then please contact a veterinarian.

Amara H. Estrada, DVM, Diplomate ACVIM (Cardiology)