



Amara H. Estrada, DVM, DACVIM (Cardiology)

Name: Hansberger, Flynn
Signalment:
Birthdate: 03/19/2018
Weight: 6.9 kg

Date: 05/26/2021
Veterinarian:
Hospital:

History and Cardiovascular Exam

Cardiovascular Exam:

BAR, moderately agitated, MM pink, jugular veins normal, heart rate: 228 bpm, regular rhythm, no murmur, respiratory rate: 60 eupneic, lungs clear, eupneic, femoral pulses normal.

Diagnostic Findings

Echo Study: This was a technically difficult study with suboptimal views due to patient demeanor.

Left Ventricle: The left ventricular chamber size, wall thickness, and systolic function are normal.

Left Atrium: The left atrial size is normal.

Right Ventricle: The right ventricular chamber size, wall thickness, and systolic function are subjectively normal.

Right Atrium: The right atrial size is subjectively normal.

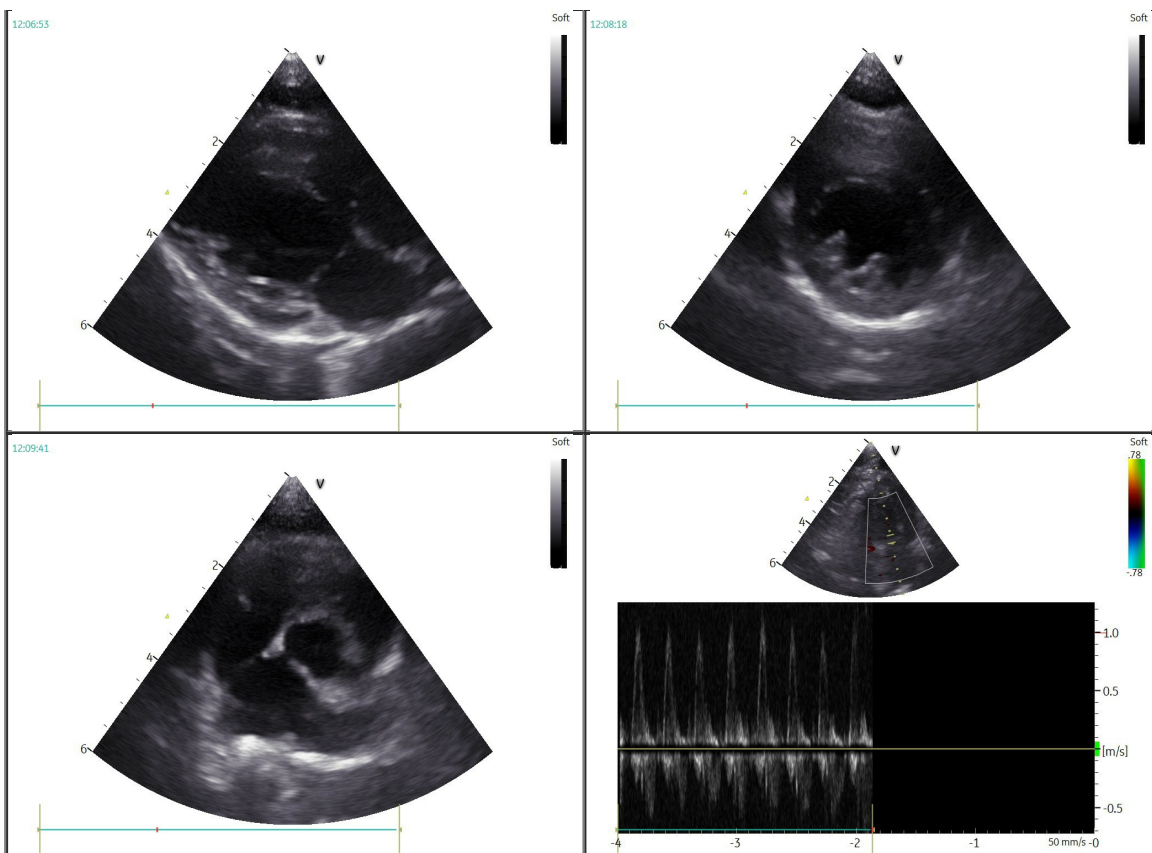
Aortic Valve: The aortic valve is trileaflet, and appears structurally normal, with normal flow across the valve in systole and no insufficiency.

Mitral Valve: The mitral valve appears normal and there is no regurgitation.

Tricuspid Valve: The tricuspid valve appears normal in structure.

Pulmonic Valve: The pulmonic valve appears structurally normal with normal Doppler flow across the valve in systole.

2D		M-Mode		Doppler	
IVSd	0.47 cm	IVSd	0.47 cm	AV Vmax	1.05 m/s
LVIDd	1.80 cm	LVIDd	1.85 cm	AV maxPG	4.39 mmHg
LVPWd	0.50 cm	LVPWd	0.42 cm	RVOT Vmax	1.18 m/s
LVIDdn	1.018	IVSs	0.60 cm	RVOT maxPG	5.60 mmHg
IVSs	0.67 cm	LVIDs	0.78 cm		
LVIDs	0.83 cm	LVPWs	0.86 cm		
LVPWs	0.82 cm	%FS	57.89%		
%FS	53.90%	RWT	0.45		
Ao Diam	1.06 cm	LVIDdn	1.047		
LA Diam	1.33 cm				
LA/Ao	1.25				



Clinical Diagnosis

Structurally and functionally normal heart

Treatment and Recommendations

Today, Flynn's heart is structurally and functionally normal based on the echocardiogram. There are no medications indicated at this time.

Since Flynn is of a breed that is at risk of developing heart disease, periodic rechecks are recommended. Additionally, if you notice any signs that may be consistent with heart disease such as lethargy, decreased appetite, coughing, weakness/collapse, increased respiratory effort or rate then please contact a veterinarian.

Amara H. Estrada, DVM, Diplomate ACVIM (Cardiology)