



Amara H. Estrada, DVM, DACVIM (Cardiology)

**Name:** Hansberger, Kiara  
**Signalment:**  
**Birthdate:** 08/03/2018  
**Weight:** 4.7 kg

**Date:** 05/26/2021  
**Veterinarian:**  
**Hospital:**

### History and Cardiovascular Exam

Cardiovascular Exam:

BAR, MM pink, jugular veins normal, heart rate: 216 bpm, regular rhythm, no murmur, respiratory rate: 42 eupneic, lungs clear, eupneic, femoral pulses normal. BCS 3/9

### Diagnostic Findings

Echo Study: Good image quality for this study.

Left Ventricle: The left ventricular chamber size, wall thickness, and systolic function are normal.

Left Atrium: The left atrial size is normal.

Right Ventricle: The right ventricular chamber size, wall thickness, and systolic function are subjectively normal.

Right Atrium: The right atrial size is subjectively normal.

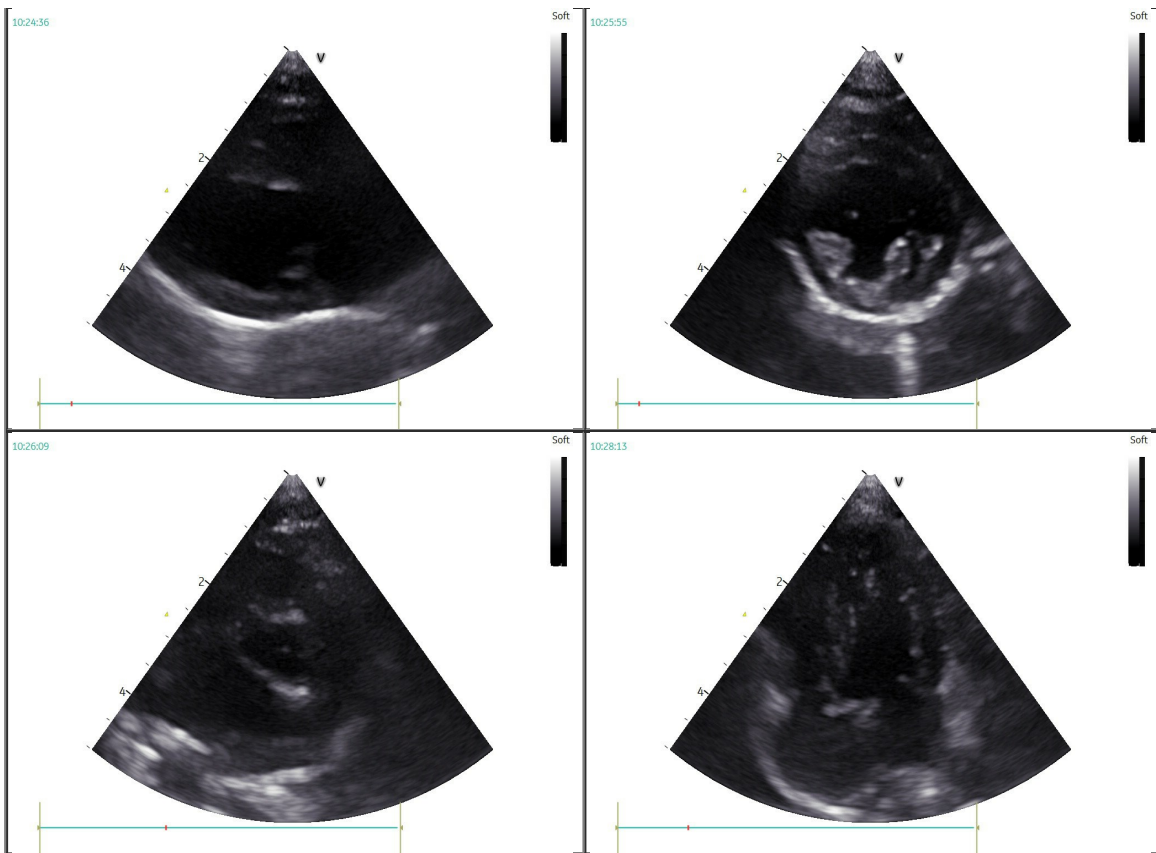
Aortic Valve: The aortic valve is trileaflet, and appears structurally normal, with normal flow across the valve in systole and no insufficiency.

Mitral Valve: The mitral valve appears normal and there is no regurgitation.

Tricuspid Valve: The tricuspid valve appears normal in structure.

Pulmonic Valve: The pulmonic valve appears structurally normal with normal Doppler flow across the valve in systole.

<b>2D</b>		<b>M-Mode</b>		<b>Doppler</b>	
IVSd	0.39 cm	IVSd	0.44 cm	MV E Vel	0.53 m/s
LVIDd	1.69 cm	LVIDd	1.60 cm	MV E/A Ratio	1.26
LVPWd	0.43 cm	LVPWd	0.35 cm	MV A Vel	0.42 m/s
LVIDdn	1.069	IVSs	0.73 cm	AV Vmax	1.16 m/s
IVSs	0.48 cm	LVIDs	0.90 cm	AV maxPG	5.36 mmHg
LVIDs	0.95 cm	LVPWs	0.64 cm	RVOT Vmax	0.82 m/s
LVPWs	0.66 cm	%FS	43.48 %	RVOT	2.66 mmHg
%FS	43.51 %	RWT	0.43	maxPG	
Ao Diam	0.90 cm	LVIDdn	1.013		
LA Diam	1.27 cm				
LA/Ao	1.40				



### Clinical Diagnosis

Structurally and functionally normal heart

### Treatment and Recommendations

Today, Kiara's heart is structurally and functionally normal based on the echocardiogram. There are no medications indicated at this time.

Since Kiara is of a breed that is at risk of developing heart disease, periodic rechecks are recommended. Additionally, if you notice any signs that may be consistent with heart disease such as lethargy, decreased appetite, coughing, weakness/collapse, increased respiratory effort or rate then please contact a veterinarian.

**Amara H. Estrada, DVM, Diplomate ACVIM (Cardiology)**